

Combined Spinal Epidural Overcoming a Lumbar Lipoma for Lower Limb Both Bone Fracture

Robin S Chacko¹, Krishna Prasad Thangarasu², Hariesh Annamalai³

ABSTRACT

Lipomas are a commonly occurring tumor and this particular one brought about challenges to our plan of anesthesia owing to its location. General anesthesia was unwarranted owing to the nature of the surgery as well as the COPD that the patient was suffering from. With meticulous technique and good knowledge of anatomy, we safely executed combined spinal-epidural anesthesia for our patient, the highlight being threading the epidural catheter downward above the lipoma to position it optimally and administering the subarachnoid block from below the lipoma, which resulted in satisfactory intra- and postoperative outcomes.

Keywords: Anesthesia, Epidural, Lipoma, Spinal.

Research and Innovation in Anesthesia (2021): 10.5005/jp-journals-10049-0103

INTRODUCTION

A lipoma in the vicinity of neuraxial blockade requires detailed evaluation since any extension of the swelling into the epidural space as an epidural lipomatosis, though rare,¹ can make a spread of local anesthetic and reliability of neuraxial blockade questionable.² The choice of anesthetic technique depends on many factors but it is mainly the absolute and/or relative contraindications that guide the anesthesiologists in determining the best technique applicable for a case.³

In this case report, the patient was an elderly COPD patient who suffered a left leg both bone fracture and was posted for intramedullary interlocking nailing. A neuraxial technique was considered but the patient was found to have a soft tissue benign tumor extending over the lumbar area during pre-op evaluation. Successful placement of an epidural catheter above the lipoma was performed followed by subarachnoid block below and surgery was performed safely as planned.

CASE DESCRIPTION

A 70-year-old man who was a chronic smoker and diagnosed with COPD and a history of frequent exacerbations suffered an RTA and sustained left leg both bone fractures. The patient was posted for an IMIL nailing operation of the tibia. During a pre-anesthetic checkup, the patient was planned for central neuraxial blockade owing to the comorbidities and site of surgery. Airway examination did not predict any difficulties and routine investigations including ECG, chest X-ray, and vitals were within normal limits. However, physical examination revealed a soft tissue swelling in the lumbar region of the back extending from T11 to L2.

A general surgery consult was sought to evaluate the swelling and was diagnosed as a subcutaneous lipoma. A complete neurological examination revealed no sensory or motor deficits and all reflexes were intact as well and an MRI confirmed there was no invasion into epidural space. The patient was assessed fit under ASA II. The plan of anesthesia was explained to the patient and informed written consent for the same was obtained the night before surgery.

¹⁻³Department of Anaesthesiology, Shri Sathya Sai Medical College and Research Institute, Chengalpattu, Tamil Nadu, India

Corresponding Author: Robin S Chacko, Department of Anaesthesiology, Shri Sathya Sai Medical College and Research Institute, Chengalpattu, Tamil Nadu, India, Phone: +91 9496140000, e-mail: robinsajan@hotmail.com

How to cite this article: Chacko RS, Thangarasu KP, Annamalai H. Combined Spinal Epidural Overcoming a Lumbar Lipoma for Lower Limb Both Bone Fracture. *Res Inno in Anesth* 2021;6(2):44–45.

Source of support: Nil

Conflict of interest: None

Anesthetic Management

On the morning of surgery, the patient was shifted to the operating room after a quick assessment within the preoperative holding area ensuring NPO was maintained, morning doses of nebulization were given, and no new symptoms had occurred. Standard monitors were connected and baseline vitals were recorded. The patient was kept in a sitting position and subsequently, his thoracolumbar region was painted with betadine followed by surgical spirit, mopped dry, and draped with a center hole towel under aseptic precautions (Fig. 1).

After infiltrating skin of the target area with 2% lignocaine, an 18-G Tuohy's epidural needle from a Portex epidural kit was inserted above the lipoma in T9-T10 space with the bevel facing downward. The epidural space was identified at a depth of 4.5 cm using a loss of resistance to air technique. The epidural catheter was inserted, threaded downward without any undue resistance, and fixed at 10 cm after ensuring a negative test dose with 3 mL of 1.5% lignocaine with adrenaline 1:200,000 (Fig. 2). Following this, a 23-G Quincke's spinal needle was inserted in the L3-L4 intervertebral space and 3.5 mL of hyperbaric 0.5% bupivacaine was injected intrathecally. The patient was put to supine position and once a sensory block to T8 level was achieved, the surgeons were instructed to proceed toward initiating the surgery.

There were no adverse intraoperative events throughout the surgery which lasted for a total period of 3 hours and 10 minutes,

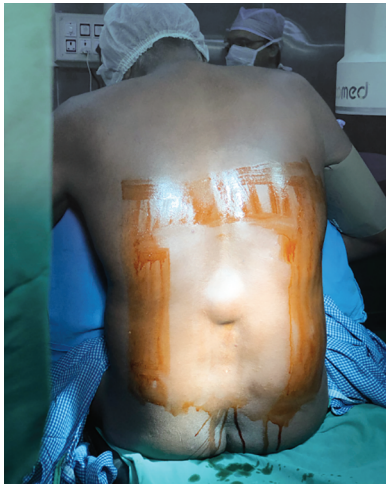

Fig. 1: Lumbar lipoma

requiring a total of two titrated epidural top-ups of 10 mL 0.5% bupivacaine each. Postoperatively, the patient was shifted to surgical ICU where a continuous infusion of 0.125% bupivacaine was given at 5 mL/hour for the next 2 days. The catheter was removed afterward during which it was examined for any damage but did not seem to have any and appeared intact. The postoperative period was uneventful except for a mild exacerbation of COPD which settled with routine nebulizations using salbutamol and budesonide.

DISCUSSION

From the patient's preexisting lung condition as well as the nature of the surgical intervention planned, it is evident that regional anesthesia would be the mode of choice. The safety profile along with better postoperative outcomes of combined spinal-epidural anesthesia over GA has been well established.⁴

A sole epidural would require large volumes of a concentrated local anesthetic to bring about the required level of muscle relaxation for the surgery. This predisposes the patient to high doses of local anesthetic and also brings about greater hemodynamic instability. Hence, the better option would be to opt for a combined spinal-epidural technique,⁵ whereby the subarachnoid block would create the dense block at low levels and the epidural would supplement intraoperative anesthesia and well as provide safe and effective postoperative analgesia. A caudal epidural technique was abandoned owing to its technical difficulty in adults, high failure rate, and a relatively large volume of drug required.³

We avoided attempting to administer subarachnoid block or thread epidural catheter through the lipoma since there have been previous case reports of seeding of tumor cells into the epidural space when needles have been inserted through tumors, which in our case lies at the lumbar region at what would have been the ideal site for epidural needle insertion. Doing so would require constant follow-up of the patient to screen him for the development of iatrogenic epidural lipomatosis which, although rare, can occur and may even compress the spinal cord causing potentially debilitating neurological deficits.⁶

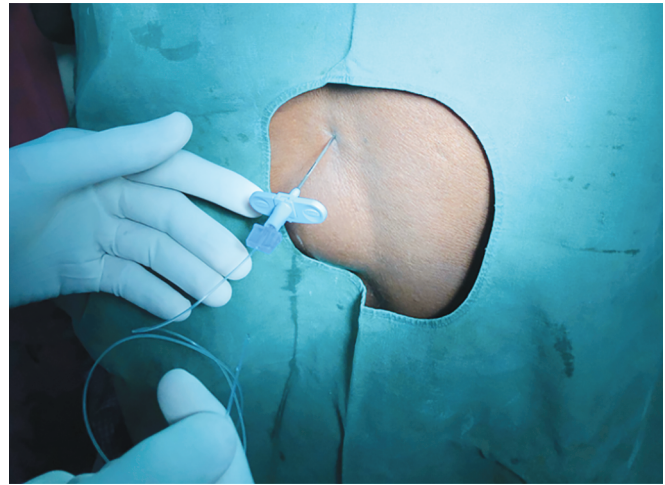


Fig. 2: Epidural catheter threaded caudally

During the preoperative assessment, we did a detailed evaluation of the tumor including an MRI to clearly map out the extent of the tumor. If the tumor was not merely a subcutaneous swelling as it appeared to be and was invading into the epidural space altering its anatomy, then the spread of local anesthetic within the epidural and subarachnoid space and thereby the reliability of the neuraxial technique itself would become questionable and unpredictable.² Fortunately, the tumor was well within the subcutaneous region and nowhere in the vicinity of the spinal canal.

The location of this lipoma did pose some challenges for our anesthetic plan. But with careful research and detailed evaluation, the decision was made to proceed with combined spinal-epidural technique as the plan of anesthesia. The pre-op, intra-op, and postoperative period was uneventful with no remarkable adverse effects occurring throughout the surgery which lasted for about 3 hours 10 minutes.

REFERENCES

1. Fogel GR, Cunningham III PY, Esses SI. Spinal epidural lipomatosis: case reports, literature review and meta-analysis. *Spine J* 2005;5(2):202–211. DOI: 10.1016/j.spinee.2004.05.252.
2. Thompson MD, Vasdev GM, Findlay JY. Epidural blockade for labor and cesarean section with associated L4-5 lipomyelocoele. *Anesthesiology* 1999;90(4):1217–1218. DOI: 10.1097/00000542-199904000-00042.
3. Saied NN, Helwani M. Successful lumbar epidural catheter placement through a lower back lipoma. *Saudi J Anaesthesia* 2013;7(1):83. DOI: 10.4103/1658-354X.109826.
4. Rodgers A, Walker N, Schug S, et al. Reduction of postoperative mortality and morbidity with epidural or spinal anaesthesia: results from overview of randomised trials. *BMJ* 2000;321(7275):1493. DOI: 10.1136/bmj.321.7275.1493.
5. Hamdani GA, Chohan U, Zubair NA. Clinical usefulness of sequential combined spinal epidural anaesthesia in high risk geriatric patients for major orthopaedic surgery. *J Anaesth Clin Pharmacol* 2002;18(2):163–166.
6. Jeong IH, Lee JK, Moon KS, et al. Iatrogenic intraspinal epidermoid tumor: case report. *Pediatr Neurosurg* 2006;42(6):395. DOI: 10.1159/000095573.