

CASE REPORT

Management of a Case of Dropped Nucleus following Small Incision Cataract Surgery in a Patient with Thoracic Kyphoscoliosis and Review of Literature

¹Banashree Mandal, ²Deeksha Katoch, ³Sabia Handa

ABSTRACT

A curved spine accompanied by restricted neck motion poses a challenge for an ophthalmic surgeon, especially a vitreoretinal surgeon, who needs the patient's eyes in a horizontal position to operate with the microscope. Literature is sparse with case reports of thoracic kyphoscoliosis for vitreoretinal surgery, although many reports are available for cataract surgery. We report a case of thoracic kyphoscoliosis and ankylosing spondylitis with dropped nucleus into the vitreous cavity following a complicated cataract surgery posted for pars plana vitrectomy, pars plana lensectomy, and phacofragmentation under general anesthesia and review the current literature of such case.

Keywords: Extreme positioning, General anesthesia, Thoracic kyphoscoliosis, Vitreoretinal surgery.

How to cite this article: Mandal B, Katoch D, Handa S. Management of a Case of Dropped Nucleus following Small Incision Cataract Surgery in a Patient with Thoracic Kyphoscoliosis and Review of Literature. *Res Inno in Anesth* 2017;2(1):21-23.

Source of support: Nil

Conflict of interest: None

INTRODUCTION

A curved spine accompanied by restricted neck motion poses a challenge for an ophthalmic surgeon, especially a vitreoretinal surgeon, who needs the patient in a supine position and his eyes in a horizontal position to operate with the microscope. Literature is sparse with case reports of thoracic kyphoscoliosis for vitreoretinal surgery, although many reports are available for cataract surgery. Not only are such patients difficult for surgeons because of the inability to lie flat on the operating table;

they also pose difficulty in providing anesthesia due to anticipated difficult airway because of restricted neck movement, thoracic kyphoscoliosis with inherent restrictive lung disease and its implication on oxygenation and ventilation,¹⁻⁴ and need for extreme positioning like steep Trendelenburg position with its implications on hemodynamics, especially in an elderly patient. We report a case of thoracic kyphoscoliosis and ankylosing spondylitis with dropped nucleus into the vitreous cavity following a complicated cataract surgery with threatened vision posted for pars plana vitrectomy, pars plana lensectomy, and phacofragmentation under general anesthesia (GA), and review the current literature of such a case.

CASE REPORT

A 55-year-old male presented with a history of poor gain in visual acuity following a small incision cataract surgery in the right eye done elsewhere 1 day before. His past medical and surgical history revealed a double valve replacement of mitral and aortic valve, and tricuspid valve annuloplasty surgery done 4 years back for rheumatic heart disease with acute heart failure. He was also a diagnosed case of ankylosing spondylitis for the last 25 years. He was on the following medications for his systemic conditions: Tab. diltiazem 120 mg once daily (OD), tab. torsemide 20 mg + spironolactone 60 mg OD, tab. nicoumalone 4 mg OD, tab. theophylline 600 mg OD, tab. digoxin 0.125 mg OD, and tab. tamsulosin 400 mg OD. Ocular examination revealed a visual acuity of hand motion in the right and 6/6 in the left eye. Intraocular pressure was 18 (on tablet acetazolamide 250 mg tid and eye drops dorzolamide and timolol). Examination of the right eye showed subconjunctival hemorrhage, superiorly peaked pupil, aphakia, and blood clot in the anterior chamber. Posterior segment examination showed a dense vitreous hemorrhage. The left eye examination was normal. Ultrasonography of the right eye showed multiple moderate amplitude echoes in vitreous cavity suggestive of vitreous hemorrhage, and globular hyperreflective structure in the inferior vitreous cavity suggestive of dropped nucleus. The surgical plan was to do a pars plana vitrectomy and phacofragmentation under GA.

¹Associate Professor, ²Assistant Professor, ³Junior Resident

¹Department of Anesthesia and Intensive Care, Postgraduate Institute of Medical Education and Research, Chandigarh, India

^{2,3}Department of Ophthalmology, Postgraduate Institute of Medical Education and Research, Chandigarh, India

Corresponding Author: Banashree Mandal, Associate Professor, Department of Anesthesia and Intensive Care Postgraduate Institute of Medical Education and Research Chandigarh, India, Phone: +91172-2756500, e-mail: banashreemandal@yahoo.co.in

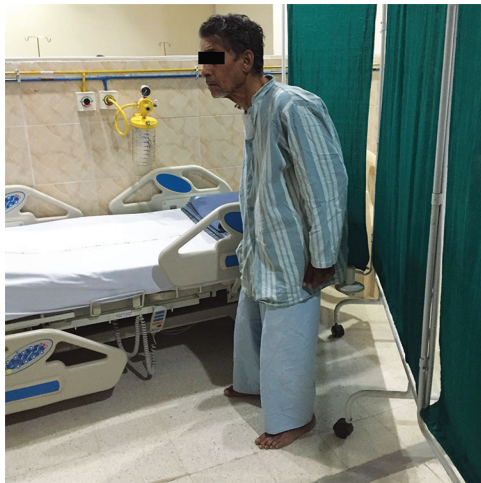

Fig. 1: Thoracic kyphoscoliosis of nearly 45°

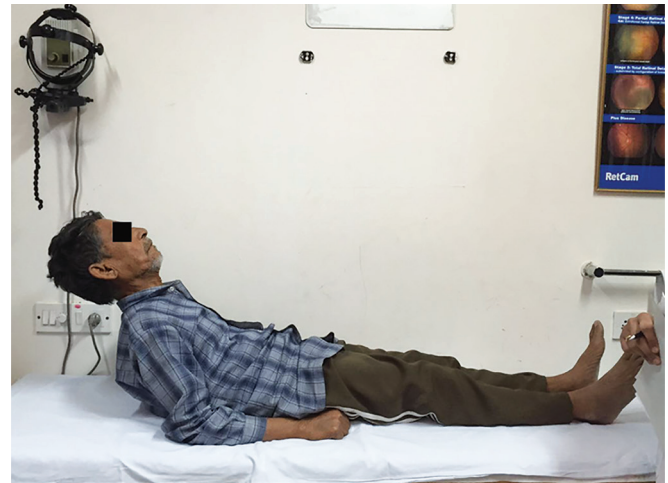

Fig. 2: Patient's inability to lie flat on the operating table

On examination, in the cardiovascular system, prosthetic valve function was normal with audible click and bilateral vesicular breath sound in respiratory system; in the skeletal system, there was a thoracic kyphoscoliosis of nearly 45° (Fig. 1). Intraoperative difficulties anticipated were: Prolonged surgical duration, poor view, and inability to maneuver surgical instruments as well as operating microscope because of patient's inability to lie flat on the operating table (Fig. 2). His cataract surgery had been done under local anesthesia, and he was unable to lie down during the procedure. Only severe Trendelenburg position of the patient would have allowed bringing his eyes in a horizontal position.

As anesthesiologists, our concern was the added adverse effect of severe Trendelenburg position on the cardiovascular and respiratory systems. In the airway examination, he had mouth opening of greater than three fingers, upper lip bite positive, thyromental distance more than 6 cm, modified Mallampati grade II with no neck extension. His breath holding time was >20 seconds. As an emergency procedure, we could not get a two-dimensional transthoracic echocardiography or pulmonary function test done. However, with his significant past surgical history, drug history, general physical status, and known restrictive pulmonary physiology of thoracic kyphoscoliosis, he was a high-risk case. Hence, the plan of anesthesia was positioning of patient in the ramp position, which we usually done for obese patients and bringing the table in the Trendelenburg position after induction of GA.

The ramp was produced with multiple pillows, and cotton pads were put to fill the gaps behind his back and the operating table, which still remained because of scoliosis and the hump on his back. Even with the ramp position, the patient was only able to lie down with his legs folded and buttocks elevated from the table. Hence, pillows were also kept below his buttocks to support them. Legs were restrained from falling down after induction of GA with

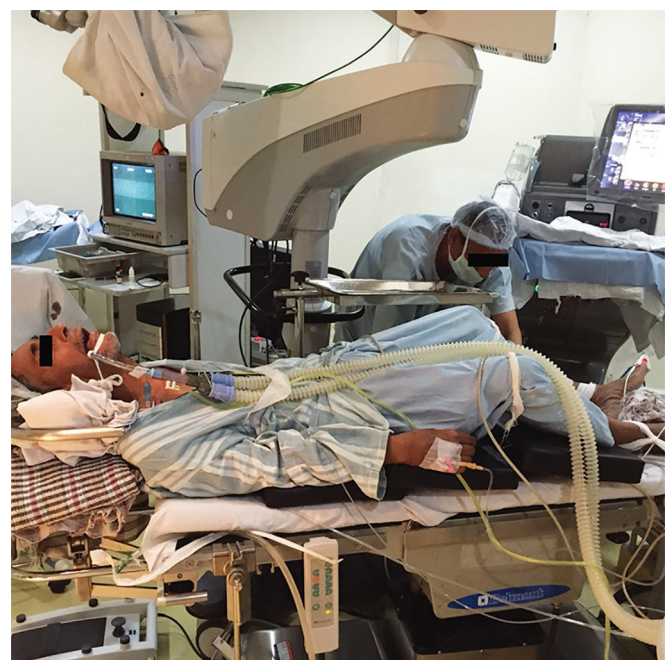


Fig. 3: Ramp position of patient

ties to the side of the operating table (Fig. 3). To take care of possible difficult intubation, a gum-elastic bougie, supraglottic device (intubating laryngeal mask airway, size 4) and fiberoptic bronchoscope were kept ready. The Standard American Society of Anesthesiologists monitoring with five-lead electrocardiogram, noninvasive blood pressure, plethysmography, and end tidal carbon dioxide monitoring was applied. Baseline vitals were within normal limits. After preoxygenation, GA was induced with propofol and, after confirming adequate mask ventilation, tracheal intubation was facilitated with nondepolarizing muscle relaxant vecuronium. His trachea was intubated with a stylated endotracheal tube. Then slight Trendelenburg position of about 45° brought the eyes into a horizontal position, as the patient's head end was naturally elevated up to 45°. Invasive lines were not

taken as mild degree of head down was done without any hemodynamic aberrations. Surgery was completed without any difficulty. Patient was discharged home after an uneventful hospital stay.

DISCUSSION

With anticipation of difficulty and proper planning and execution, we could successfully save the threatened vision in a high-risk patient. Literature is sparse with few case reports of different patient positioning and different approaches to the eyes for posterior segment ophthalmic surgery. In a recent case report by You et al,⁵ extreme head-down position was required for a fixed 90° curvature of cervical spine due to severe ankylosing spondylitis for retinal detachment repair surgery. Afshar et al⁶ reported a case of Trendelenburg positioning (25–45° head down) and surgeon having a temporal approach for vitreoretinal surgery in a patient with severe cervical kyphosis for previous cervical vertebra fusion surgery. Both cases were done under mild intravenous sedation and local anesthetic block of involved eye. Both these patients were elderly, but without any comorbidities. Hence, probably they could tolerate the extreme Trendelenburg position or surgery done under mild sedation. Our patient was much more sick and surgeons needed GA for the patient as the previous surgery done under local anesthesia went wrong probably because of improper position of patient. Our theaters are not equipped with operating tables to make such extreme positions.

CONCLUSION

A curved spine accompanied by restricted neck motion poses a challenge for vitreoretinal surgery. With anticipation

of difficulty and proper planning and execution, we could successfully position a patient of severe thoracic kyphoscoliosis to undergo an uneventful pars planovitrectomy and phacofragmentation under GA.

CLINICAL SIGNIFICANCE

- Anticipation of difficulty is important in anesthesia practice.
- Proper utilization of limited resources can lead to success.
- Positioning should be tailored to the physical status of the patient, at the same time not compromising with surgical outcomes.

REFERENCES

1. Zeng Y, Chen Z, Ma D, Guo Z, Qi Q, Li W, Sun C, Liu N, White AP. The influence of kyphosis correction surgery on pulmonary function and thoracic volume. *Spine (Phila Pa 1976)* 2014 Oct;39(21):1777-1784.
2. Caro CG, Dubois AB. Pulmonary function in kyphoscoliosis. *Thorax* 1961 Sep;16:282-290.
3. Tsiligiannis T, Grivas T. Pulmonary function in children with idiopathic scoliosis. *Scoliosis* 2012 Mar;7(1):7.
4. Menon B, Aggarwal B. Influence of spinal deformity on pulmonary function, arterial blood gas values, and exercise capacity in thoracic kyphoscoliosis. *Neurosciences (Riyadh)* 2007 Oct;12(4):293-298.
5. You T, Huang CX, Chen S, Maggiano J, Rathod R, Chang E, Casiano M. Case Report: extreme patient positioning for retinal surgery in advanced kyphosis. *Retin Cases Brief Rep* 2015 Summer;9(3):218-219.
6. Afshar AR, Pongsachareonnont P, Siegner SW, Stewart JM. Trendelenburg positioning with temporal approach for vitreoretinal surgery in a patient with severe kyphosis. *Eye (Lond)* 2014 Oct;28(10):1261-1263.